

## Perforated Olecranon Fossa in Humerus

Sayee Rajangam\*, Vidhya R.\*\*

### Abstract

**Context:** Olecranon fossa in humerus may be perforated. The perforated olecranon fossa, in general is reported associated to the left humerus and humerus of the female sex. **Aims:** In the present study, it is aimed to find out the occurrence of the perforated olecranon fossa in the humerus. **Settings and Designs:** Department of Anatomy, International Medical School, Bangalore. **Methods and Materials:** 44 humerus were available in the institute; out of which, 22 each belonged to the right and left sides. The subjective sex determination could identify 24 as male and 20 as the female humerus. **Statistical Analysis:** The percentage analysis was done. **Results:** The perforated olecranon fossa was observed in 17 (38.6%) humerus. Their presence was found to be associated to the left (50%) and the female (50%) humerus. **Conclusion:** The finding could be of significance, academically for the anatomists and anthropologists and clinically for the radiologists and orthopedic surgeons for the transhumeral approach for the elbow arthroscopy.

**Keywords:** Perforation; Olecranon fossa; Humerus.

### Introduction

Olecranon fossa, a deep hollow structure in the posterior surface of the distal end of the humerus lodges the tip of the olecranon process of the ulna during the extension of the elbow. The bone in the floor of the fossa is thin and may be partially deficient. The perforation is known as supratrochlear foramen (STF) or septal aperture. It is reported that the occurrence of the perforated olecranon fossa is more frequent in female and in left humerus (Godycki 1957)(cited in Krogman 1962). The reported incidence of STF in a South Indian study was 28% (Singhal and Rao 2007) and in a North Indian study was 24.1% (Diwan *et al* 2013). Further,

Singhal and Rao (2007) have reported that the incidence of STF in different races ranged from 6 to 60%. The present study is aimed to report the occurrence of the perforation in the olecranon fossa i.e. STF in humerus.

### Material & Method

The available humeri in the institute was 44; out of which right and left humerus were 22 each respectively. Subjective sexing based on the length, heaviness, girth and the roughness of the attachments of the muscles identified, that the male and female bones were 24 and 20. The percentage occurrence of the perforation in the olecranon fossa was calculated.

### Result

The findings are tabulated. (Figure 1)

The olecranon fossa was perforated in 17 humerus and the rest (27) had a bony plate or septum.

---

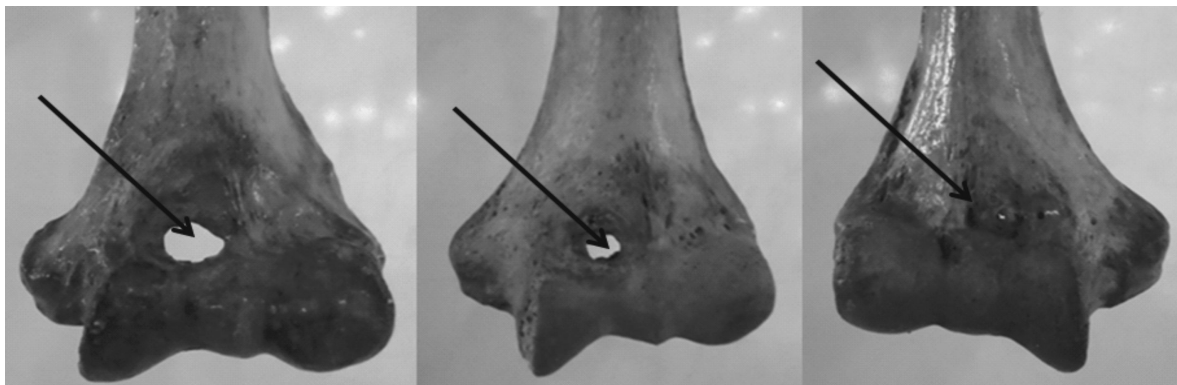
**Author's Affiliation:** \*Professor, \*\*Lecturer, Department of Anatomy, International Medical School, New BEL Road, Bangalore 560054, Karnataka, India.

**Reprint's Request:** Dr. Sayee Rajanagm, Professor, Department of Anatomy, International Medical School, New BEL Road, Bangalore 560054, Karnataka, India.

E-mail: drsayee@gmail.com

**Table 1: Perforated Olecranon Fossa**

Total number of humerus: 44; Foramen present: 17 (38.6%); Foramen absent: 27 (61.4%)				
Total number of humerus: Right side: 22		Total number of humerus: Left side: 22		
Foramen present: 06 (27.3%)		Foramen present: 11 (50%)		
Foramen absent: 16		Foramen absent: 11		
Total number of humerus: Male 24		Total number of humerus: Female: 20		
Foramen present: 07 (29%)		Foramen present: 10 (50%)		
Foramen absent: 17		Foramen absent: 10 (50%)		
	Right n22		Left n22	
Foramen	Male n11	Female n11	Male n13	Female n9
Present n17	03 (27.2%)	03 (27.2%)	04 (30.7%)	07 (77.7%)
Absent n27	08	08	09	02

**Figure 1: Arrows Indicate the Variations in the Size and Shape of the Perforations in Olecranon Fossa. (A): Large; (B): Medium; (C): Small.**

The perforated olecranon fossa was found to be higher in left humerus (50%) and in female humerus (50%).

On associating the sides with that of the male and female humerus, the occurrence of the perforation was higher for the left side and especially for the female humerus (77.7%). The shape of the perforation in olecranon fossa was studied; it was either large (12/44, 27.3%) or medium (24/44, 54.5%) or small (8/44, 18.2%) (Figure 1).

## Discussion

From the review of literature, it is seen, that in 1825, it was Meckel, who had first described STF in humerus. In 1832, Hardlicka observed that the perforation in the humerus seemed to be more frequent in higher primates other than man; hence, the presence of STF was considered to be an atavistic character. In 1927, Hirsh had stated that the thin plate of bone between the olecranon and coronoid fossa is always present until the age of 7 after which the bony septum occasionally becomes absorbed to form the STF (cited in Diwan *et al*

2013).

The article by Diwan *et al* (2013) indeed has reported in detail about STF: the history, its incidence in different populations in India and in different races, its occurrence as per the right/left sides and female/ male humeri, its association to the sides and female/ male humeri.

- i) *Incidence:* In the present study, in South Indian Bones, the incidence of the perforated olecranon fossa was found to be 38.6%. It is within the reported range of 6% to 60%; but, more than the reported incidence from India: Central Indians 32%; South Indians 28%; North Indians 27.56%; Eastern Indians: 27.4% (Singhal *et al* 2007, Diwan *et al* 2013).
- ii) *Incidence as per the Right and Left Sides:* The frequency of the STF was found to be more common on left side than on the right side (Godycki 1957(cited in Krogman 1962); Radi *et al* 2013) The reported range in the percentage occurrence of the STF in the right was 20.22% to 28% and in the left was 20% to 35%. (Singhal *et al* 2007, Diwan *et al*

2013) In the present study, the occurrence of the perforated olecranon fossa is found to be frequent on the left side as stated in literature. And the right (27.53%) side occurrence was within the reported range; but, on the left (50%) it was found to be very high than the range given in literature.

- iii) *Incidence in the Male and Female Humerii:* Supratrochlear foramen was more often associated to female humerii. (Godycki 1957)(cited in Krogman 1962) It was suggested that the association may be due to the 'inward curvature of the female elbow angle' (Mall 1905) (cited in Diwan *et al* 2013). In the present study too, the STF was found more common in the female humerii. But, the percentages for the male (29%) and female (50%) bones are found to be higher than what was reported in literature: Singh and Singh (1972): male (21%)/ female (38%)/ Diwan *et al* 2013: male 24.1%/ female 23.76%.

The male (n 6) to female (n 11) ratio of the occurrence of the perforated olecranon fossa in the present study is around 1:1.4; which is less than the reported male to female ratio as 1:3.7. (Godycki 1957) (cited in Krogman 1962) Of course, opinions differed, whether the perforated olecranon fossa could be an indicator for the sex determination in humerus. In general, in long bones of the limbs, the sex is determined subjectively with their morphological features and objectively with morphometry. (Godycki 1957)(cited in Krogman 1962)

- iv) *Incidence by Associating the Sides and the Sex Determined Humerii:* In a study on North Indian humerii, the STF findings were: Female: right: 15.63%/ left: 31.89%; Male: right 26.76%/ left: 21.45%. (Diwan *et al* 2013) In the present study, the STF was associated to the left side and female humerii (77.7%) and it also was similar to the reports in literature.

- v) *Shape and Size of the STF:* The shapes of

the STF have been studied (Diwan *et al*; 2013). The authors have noted either oval or round or triangular shapes of STF and have observed that the oval shape was found to be the maximum (152/428,83.06%). In the present study, it is the size of the foramen which was studied and medium size foramen was found to be the maximum (54.5%).

The interesting information gathered from the literature on the perforated olecranon fossa were:

- i) absent; in case, the humerus is small
- ii) may be obliterated by a membrane
- iii) communicates with the anterior compartment of the arm which is made possible through the enlargement of the foramen
- iv) utilized in orthopedics in the transhumeral portal for the elbow arthroscopy and if found necessary by removing the membrane. (Chow 2000)

The differences observed reflect the sample size or ethnicity or race. It appears that in Indian population, the incidence of the STF seemed to be high. Hence the presence of STF should be kept in mind before any procedures (intramedullary nailing in the lower end of humerus/pseudo-lesion appearance in X-rays) are carried out in the elbow region especially on the left side and in female.

In the present study, the higher percentages of STF in the left female humerus may be because of the sample size. In spite of the sample size, the study was undertaken as an academic interest. Moreover, the observations of the present study was based on the subjective sexing of the humerus.

The surmised interpretations for the association of presence of the perforated olecranon fossa to the left side and to the females are listed:

- i) the ossification process at the lower end of humerus and or upper end of ulna especially the olecranon process at its tip?
- ii) the biomechanics at the elbow and radio-

ulnar joints? (axis/planes/ movements/ work load) (flexion and extension/ supination and pronation/slight adduction and abduction

- iii) the oblique axis of the shaft of the ulna from its upper end to the head of the ulna at its lower end?
- iv) left cerebral dominance common in population leading to more work load and thereby to earlier the ossification, the less occurrence of STF in males and right side?
- v) the left side and the females may be because of the more 'tasks' than the right side and the males?

### Conclusion

The incidence of the STF or the perforated olecranon fossa was in 17 out of 44 humerii. It was found in 7 out of the 9 left female

humerus. Its presence definitely may of clinical significance for the interpretation of X-rays and any arthroscopy procedures at elbow.

### References

1. Krogman WM. The Human Skeleton in Forensic Medicine. Illinois, USA: Charles C Thomas Pub Ltd; 1962.
2. Chow JCY. Advanced Arthroscopy, 1<sup>st</sup> edition. Philadelphia, USA: Springer- US; 2000.
3. Diwan RK, Rani A, Rani A, Chopra J, Srivastava AK, Sharma PK, Verma RK, Pankaj AK. Incidence of Supratrochlear foramen of Humerus in North Indian Population. *Biomedical Research*. 2013;24(1):142-145.
4. Singhal S, Rao V. Supratrochlear foramen of the humerus. *Anat Sci Int*. 2007; 82: 105-107.
5. Singh S, Singh SP. A study of the supratrochlear foramen in the humerus of North Indians. *J Anat Soc India*. 1972; 21: 52-56.

**Red Flower Publication Pvt. Ltd,**

***CAPTURE YOUR MARKET***

**For advertising in this journal**

**Please contact:**

**International print and online display advertising sales**

E-mail: redflowerpppl@vsnl.net / tel: +91 11 22754205, 45796900

**Recruitment and Classified Advertising**

E-mail: redflowerpppl@vsnl.net / tel: +91 11 22754205, 45796900